Bones of
Pectoral Girdle and Arm

Dr.Attaullah

People who make the choice to study, work hard or do whatever they endeavor is to give it the max on themselves to reach to the top level.

Clavicle

- The clavicle (collarbone) extends between the manubrium of the sternum and the acromion of the scapula.

- It is classed as a long bone, and can be palpated along its length. In thin individuals, it is visible under the skin. The clavicle has three main functions:

- Attaches the upper limb to the trunk as part of the ‘shoulder girdle’.
- Protects the underlying neurovascular structures supplying the upper limb.
- Transmits force from the upper limb to the axial skeleton.

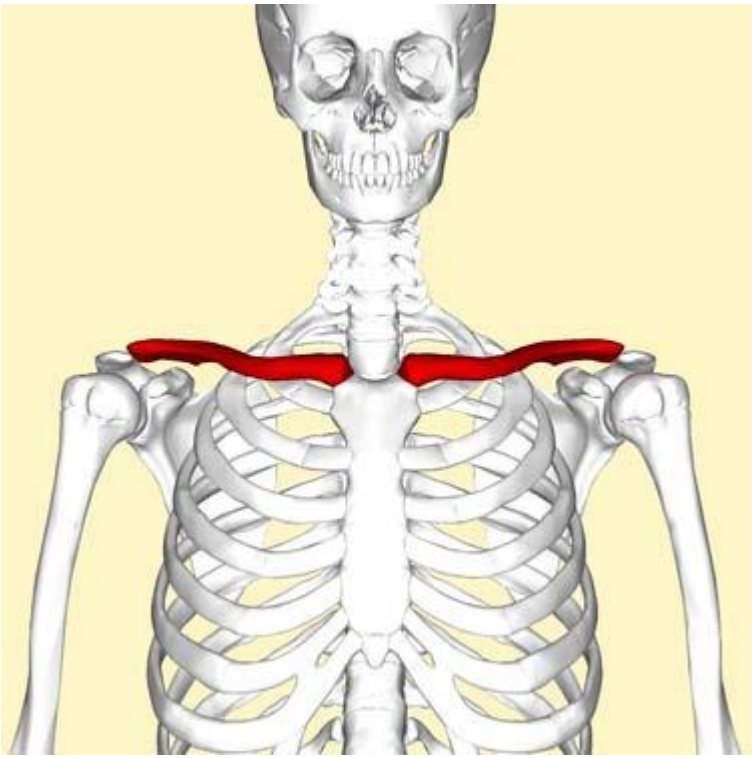

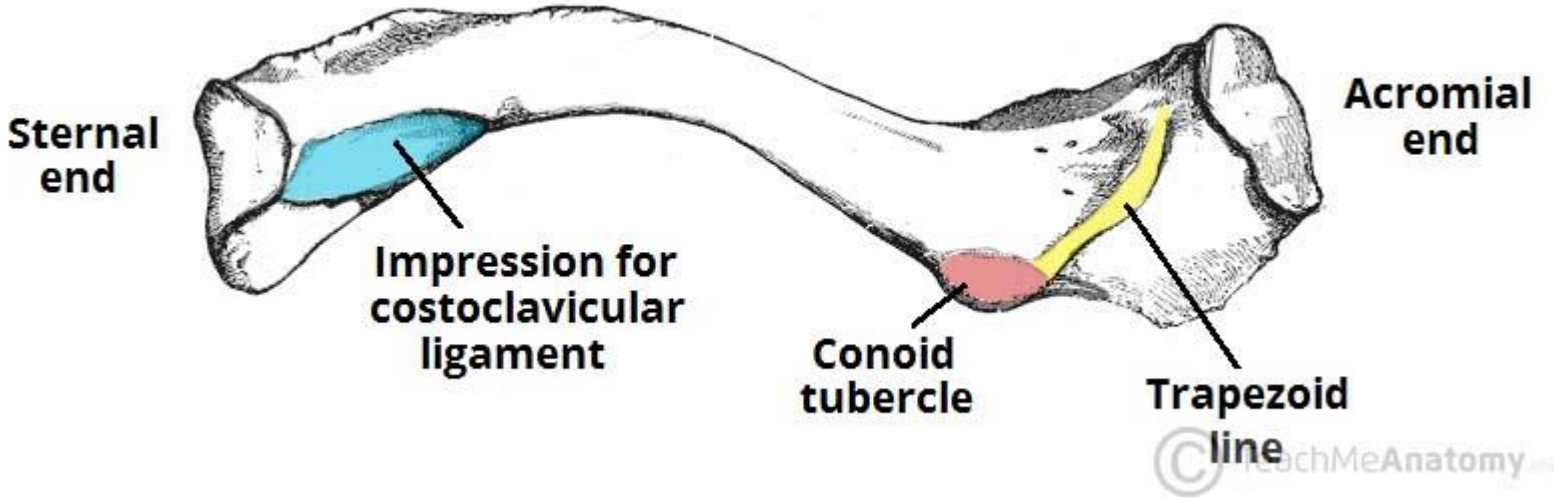
Sternal end
Acromial end
Impression for costoclavicular ligament
Conoid tubercle
Trapezoid line
© TeachMeAnatomy

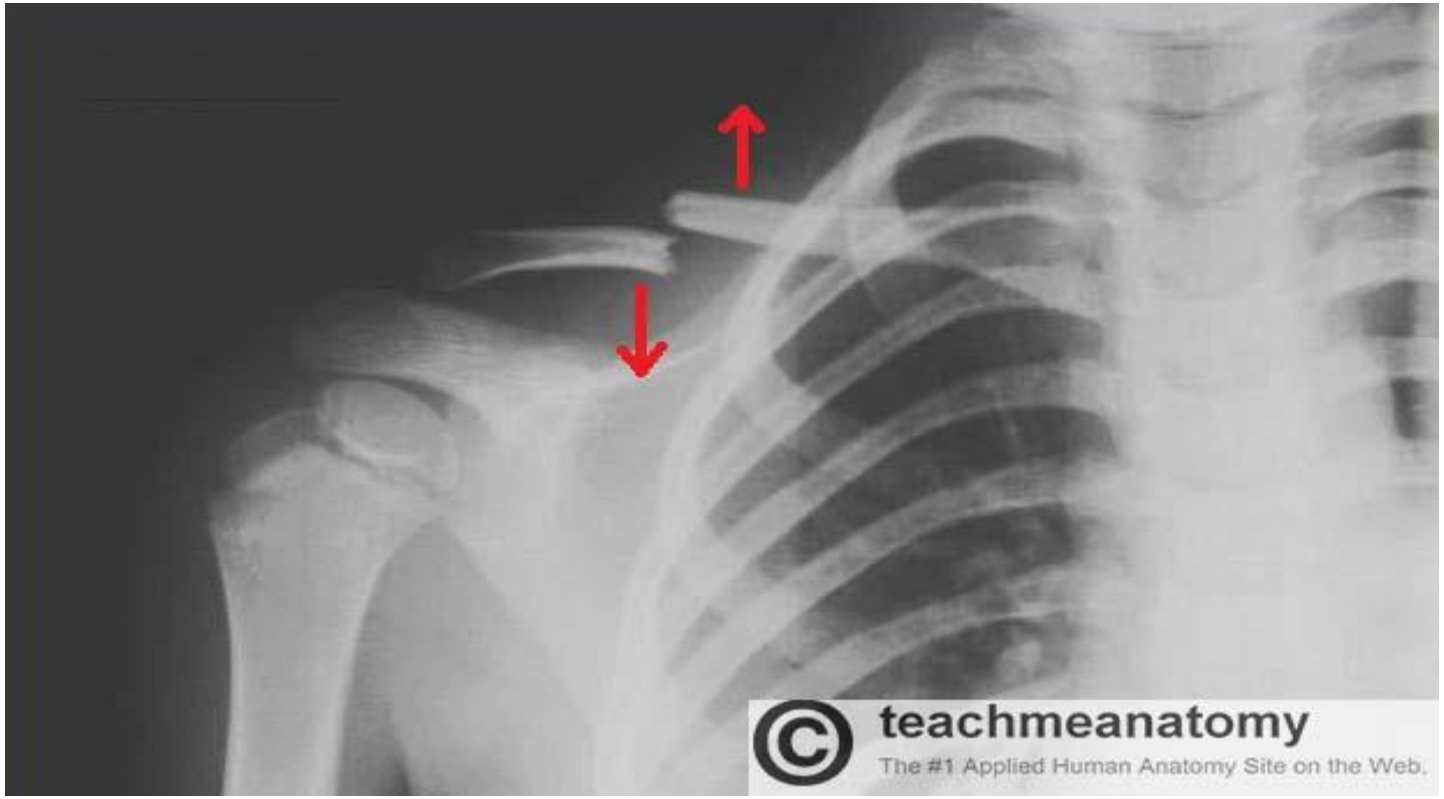
© teachmeanatomy
The #1 Applied Human Anatomy Site on the Web.

Bony Landmarks and Articulations

- The clavicle is a slender bone with an ‘S’ shape. Facing forward, the medial aspect is convex, and the lateral aspect concave. It can be divided into a sternal end, a shaft and an acromial end.
- **Sternal (medial) End**
- The sternal end contains a **large facet** – for articulation with the manubrium of the sternum at the sternoclavicular joint.
- **Shaft**
- The shaft of the clavicle acts a point of origin and attachment for several muscles – deltoid, trapezius, subclavius, pectoralis major, sternocleidomastoid and sternohyoid
- **Acromial (lateral) End**
- The acromial end houses a small facet for articulation with the acromion of the scapula at the acromioclavicular joint.

Scapula

- The **scapula** is also known as the shoulder blade. It articulates with the humerus at the glenohumeral joint, and with the clavicle at the acromioclavicular joint. In doing so, the scapula connects the upper limb to the trunk.
- It is a **triangular**, flat bone, which serves as a site for attachment for many (17!) muscle

Costal Surface

- The costal (anterior) surface of the scapula faces the **ribcage**.
- It contains a large concave depression over most of its surface, known as the **subscapular fossa**. The subscapularis (rotator cuff muscle) originates from this fossa.

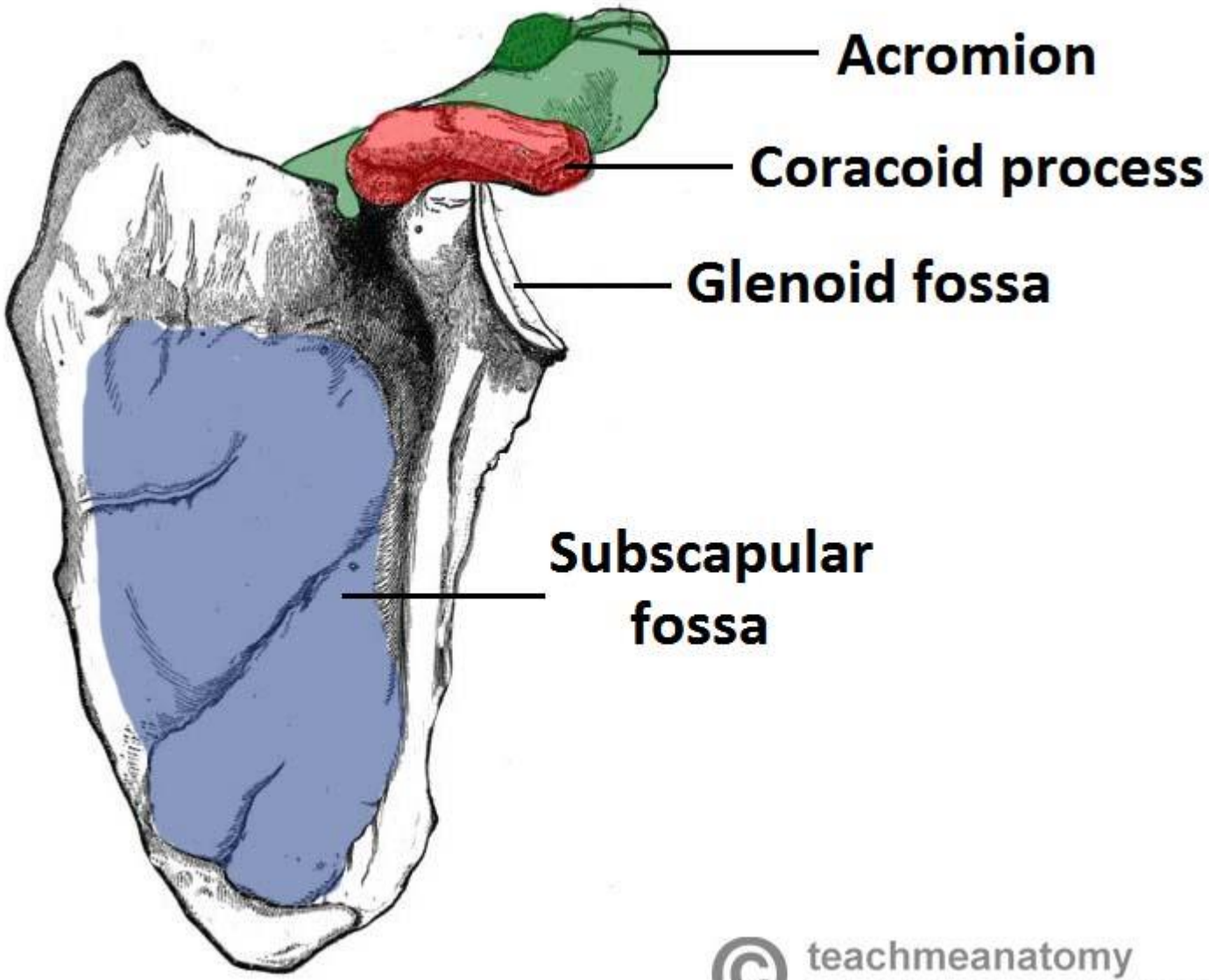

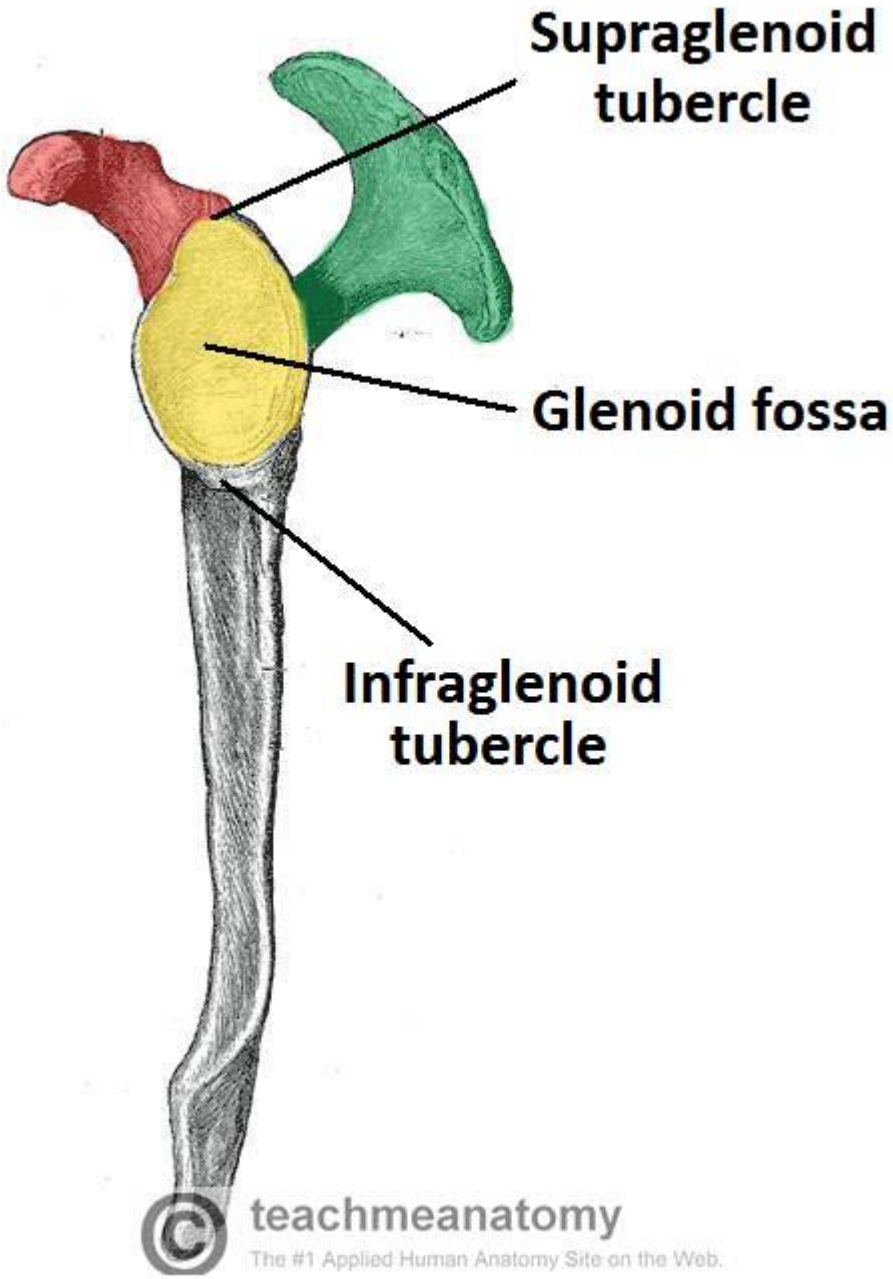

Lateral Surface

- The lateral surface of the scapula faces the humerus. It is the site of the glenohumeral joint, and of various muscle attachments. Its important bony landmarks include:
- **Glenoid fossa** – a shallow cavity, located superiorly on the lateral border.
  - It articulates with the head of the humerus to form the glenohumeral (shoulder) joint.
- **Supraglenoid tubercle** – a roughening immediately superior to the glenoid fossa.
  - The place of attachment of the long head of the biceps brachii.
- **Infraglenoid tubercle** – a roughening immediately inferior to the glenoid fossa.
  - The place of attachment of the long head of the triceps brachii.

Posterior Surface

- The **posterior surface** of the scapula faces outwards. It is a site of origin for the majority of the rotator cuff muscles of the shoulder.
- It is marked by:
- **Spine** – the most prominent feature of the posterior scapula.
- **Acromion** – projection of the spine that arches over the glenohumeral joint and articulates with the clavicle at the acromioclavicular joint.
- **Infraspinous fossa** – the area below the spine of the scapula, it displays a convex shape.
  - The infraspinatus muscle originates from this area.
- **Supraspinous fossa** – the area above the spine of the scapula, it is much smaller than the infraspinous fossa, and is more convex in shape.
  - The supraspinatus muscle originates from this area.

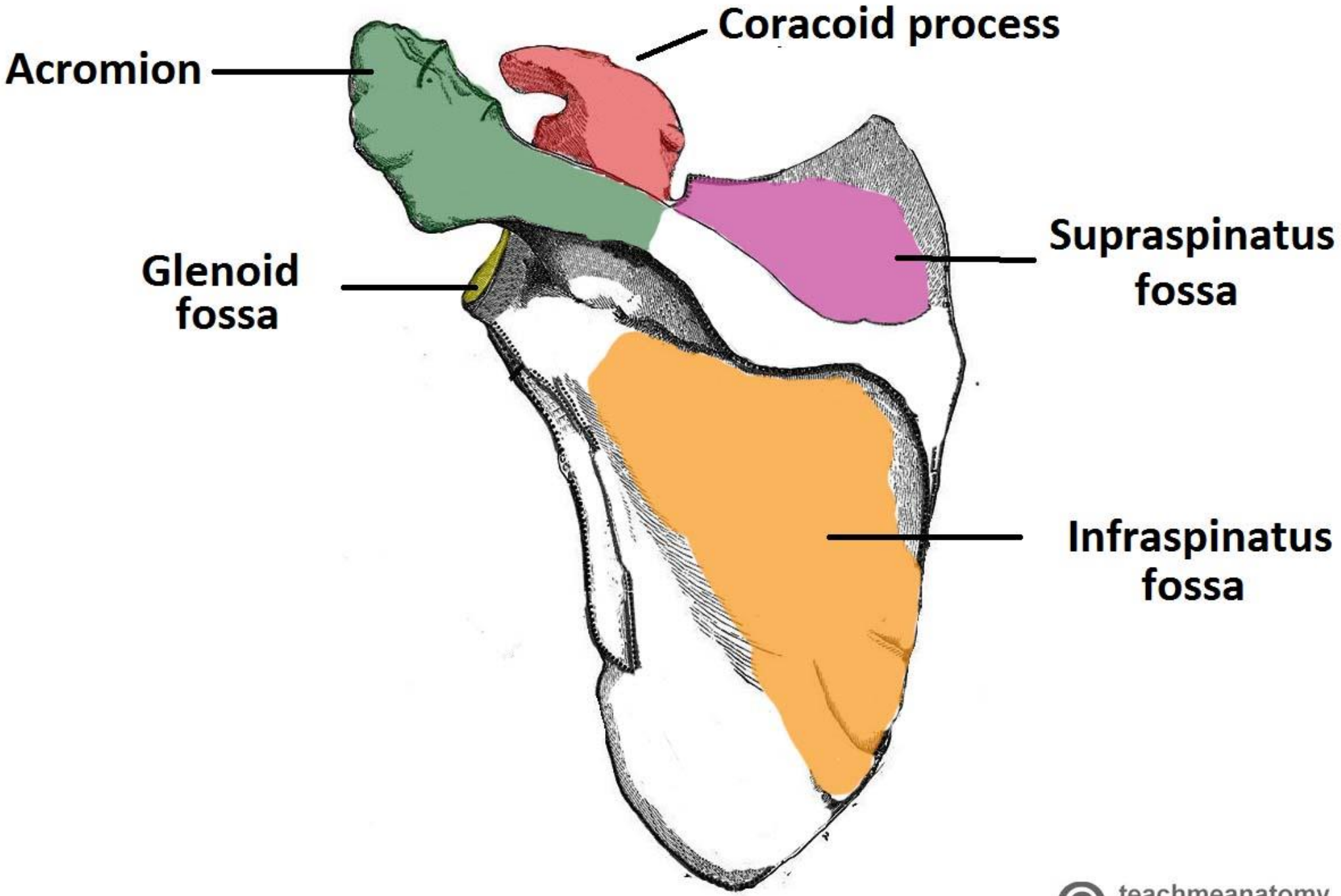

Articulations

- The scapula has two main articulations:
- **Glenohumeral joint** – between the glenoid fossa of the scapula and the head of the humerus.
- **Acromioclavicular joint** – between the acromion of the scapula and the clavicle

Humerus

- The **humerus** is a long bone of the upper limb, which extends from the shoulder to the elbow.
- The proximal region of the humerus articulates with the glenoid fossa of the scapula, forming the glenohumeral joint.
- Distally, at the elbow joint, the humerus articulates with the **head of the radius** and trochlear notch of the ulna.

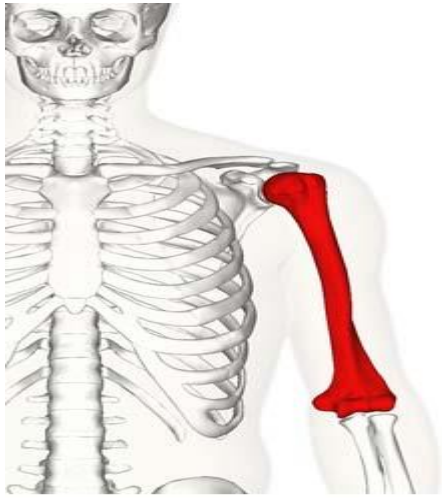

Proximal Landmarks

- The **proximal humerus** is marked by a head, anatomical neck, surgical neck, greater and lesser tubercles and intertubercular sulcus (a tubercle is a round nodule, and signifies the attachment site of a muscle or ligament).
- The upper end of the humerus consists of the **head**. This faces medially, upwards and backwards and is separated from the greater and lesser tubercle by the anatomical neck.
- The **greater tubercle** is located laterally on the humerus. It has an anterior and posterior face. The greater tubercle serves as attachment site for three of the **rotator cuff muscles** – supraspinatus, infraspinatus and teres minor – they attach to superior, middle and inferior facets respectively.
- The **lesser tubercle** is much smaller, and more medially located on the bone. It only has an anterior face. It provides attachment for the last rotator cuff muscle; subscapularis.
- Separating the two tubercles is a deep depression, called the **intertubercular sulcus**, or groove. The tendon of the long head of biceps brachii emerges from the shoulder joint and runs through this groove.

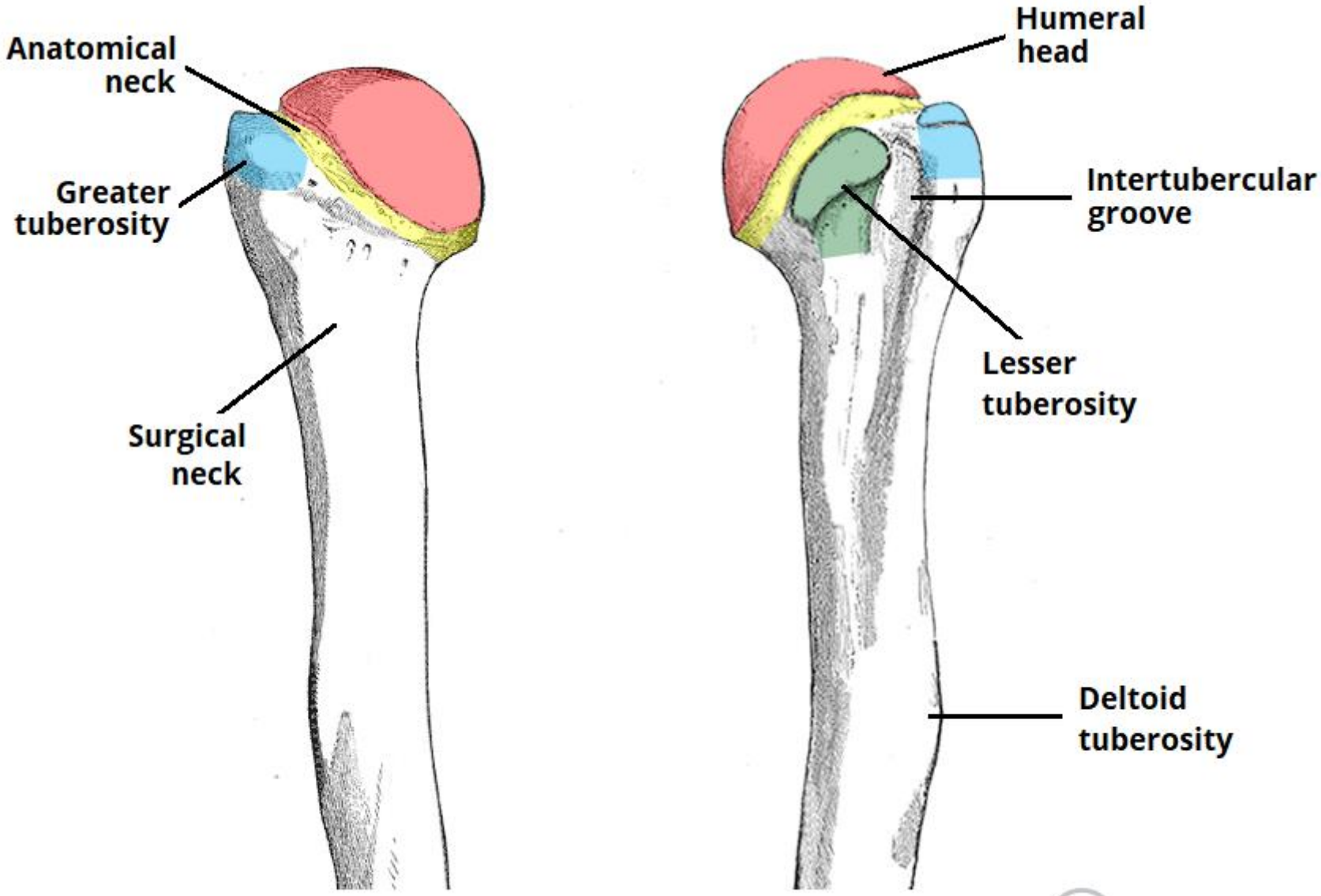

(i) Posterior Face

(ii) Anterior Face

Shaft

- The **shaft** of the humerus is the site of attachment for various muscles. Cross section views reveal it to be circular proximally and flattened distally.
- On the lateral side of the humeral shaft is a roughened surface where the deltoid muscle attaches. This is known is as the **deltoid tuberosity**.
- **Anteriorly** – coracobrachialis, deltoid, brachialis, brachioradialis.
- **Posteriorly** – medial and lateral heads of the triceps (the spiral groove demarcates their respective origins).

Distal Region

- The lateral and medial borders of the distal humerus form medial and lateral **supraepicondylar ridges**.
- The lateral supraepicondylar ridge is more roughened, providing the site of common origin of the forearm extensor muscles.
- Immediately distal to the supraepicondylar ridges are extracapsular projections of bone, the **lateral** and **medial epicondyles.**
- Both can be palpated at the elbow. The medial is the larger of the two and extends more distally. The **ulnar nerve** passes in a groove on the posterior aspect of the medial epicondyle where it is palpable.
- Distally, the **trochlea** is located medially, and extends onto the posterior aspect of the bone. Lateral to the trochlea is the **capitulum,** which articulates with the radius.
- Also located on the distal portion of the humerus are three depressions, known as the **coronoid**, **radial** and **olecranon fossae**. They accommodate the forearm bones during movement at the elbow

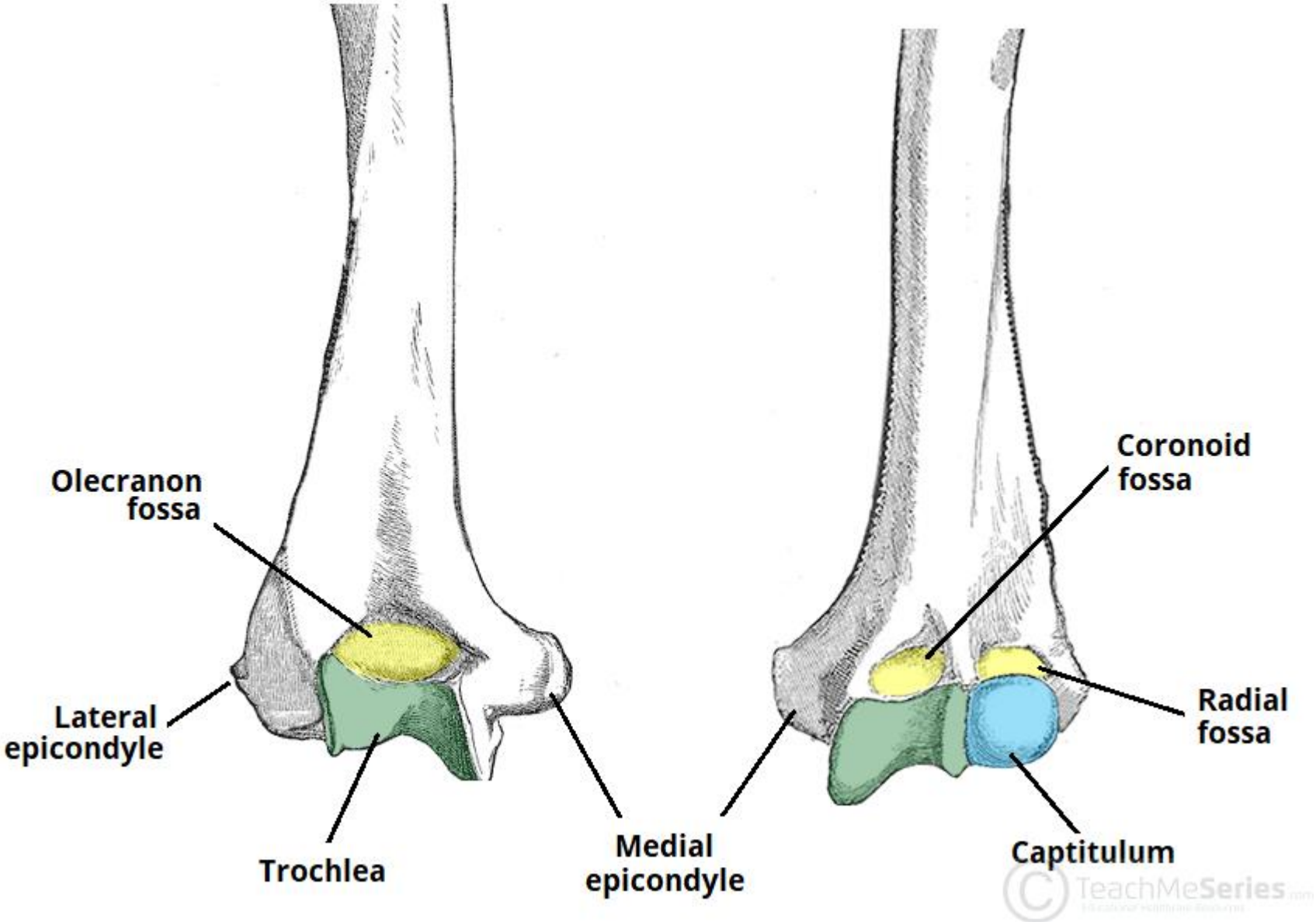
Olecranon fossa
Lateral epicondyle
Trochlea
Medial epicondyle
Coronoid fossa
Radial fossa
Captitulum
© TeachMeSeries.com

Articulations

- The proximal region of the humerus articulates with the **glenoid fossa of the scapula** to form the glenohumeral joint (shoulder joint).
- Distally, at the **elbow joint**, the capitulum of the humerus articulates with the head of the radius and the trochlea of the humerus articulates with the trochlear notch of the ulna

Thank you