

SYED

HANAYOUN

ID

13887

BIS

(D.T)

SEMESTER

6th

PAPER

OPERATIVE DENTISTRY

Submitted to

SIR USMAN.

Pg-01

Question no; (01)

Differentiate

a) Three quarter crown

b) Metal Ceramic crown

c) Seven eighth crown

ANSWER

Three Quarter crown:->

↳ The three-quarter crown on the posterior teeth probably one of the most demanding of all tooth preparations. As with such preparations on the other teeth, on a posterior molar it involves the proximal & lingual surfaces & leaves the facial surface intact.

↳ They are always made of cast metal.

Metal Ceramic Crown:->

↳ Dental porcelain can be bonded to a variety of metal alloys such as Gold, Silver, Nickel etc.

Seven Eighth Crown:->

↳ The seven-eighth crown preparation includes, in addition to the surfaces covered by the three-quarter crown, the distal half of the buccal surface.

Therefore the mesial aspect of this preparation resembles that of a three-quarter crown; the distal aspect resembles that of a complete crown.

Pg-02

Question no; (02)

In which conditions inlays & onlays are indicated & contraindicated??

ANSWER

INDICATION:->

Only Inlay & Onlay indication.

↳ They are indicated when the teeth weaken & extensively restored.

↳ Indicated for those patient who have good oral hygiene.

↳ Molar & premolar with endodontic treatment can be restored.

↳ Indicated for repeated fracture of previous restoration.

CONTRAINDICATION:->

↳ They are contraindicated when patient have abnormal function of oral structure e.g. bruxism.

↳ They do not indicate when patient have high plaque & large caries.

↳ Doesn't indicated for deep gingival preparation.

↳ They doesn't indicated when in patient under 16 because the pulp chamber is still large & dentinal tubules wide.

Pg-03

Question no; (3)

Define veneer, explain direct & indirect veneer technique?

ANSWER

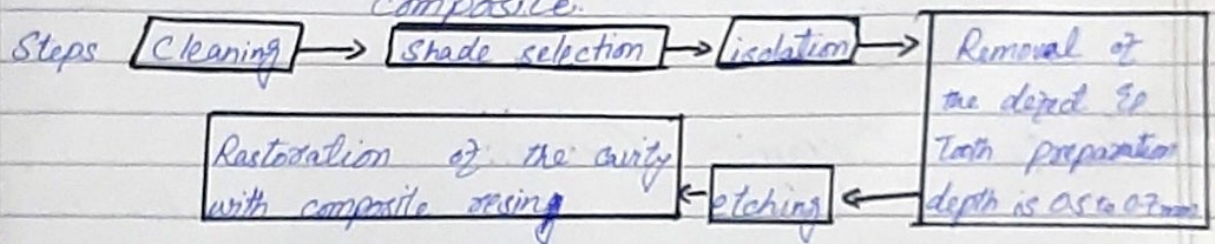
Dental Veneer:->

↳ A veneer is a layer of tooth-colored material that is applied to a tooth to restore localized defect & intrinsic discoloration

↳ Alternately known as dental laminates.

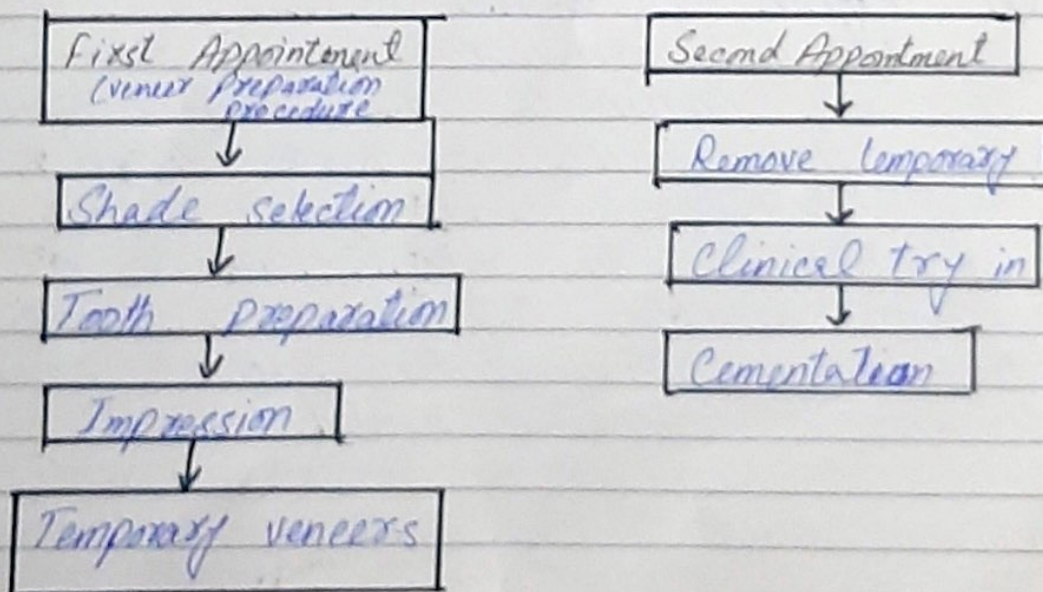
Direct Veneer Technique:->

↳ These defect can be restore in one appointment with light-cured composite.



Indirect Veneer technique:->

↳ Two appointments are required.



Pg-04

Question no; (04)

Suppose you have a crown that can be virtually indistinguishable from unrestored teeth & is most esthetically pleasing, identify the type of crown, & write its advantages, disadvantages & indications.

ANSWER.

CERAMIC CROWN:->

↳ Ceramic crown are the type of anterior complete crown for vital teeth.

↳ They are made up of translucent material which gives a very attractive look to the teeth.

ADVANTAGES:->

↳ They stop plaque accumulation.

↳ Beautiful to look & give natural look to the teeth: when dentist fit it.

↳ They are suited for those people who have minimum space on their teeth.

↳ They are made of thinner material to other crown.

DISADVANTAGES:->

↳ High cost

↳ Short duration of time

↳ Too much pressure might break the crown.

INDICATION:->

↳ High esthetic demand.

↳ Indicated for anterior teeth, that are decay, fracture or discolored etc.

Pg-005

Question no; 05

Briefly explain composite & porcelain veneers?

ANSWER.

Composite Veneers:->

- ↳ One visit procedure
- ↳ less expensive
- ↳ Repair potential
- ↳ Chair-side control of the anatomy
- ↳ Minimal irreversible loss of tooth structure
- ↳ Can be build up in the mouth by directly placing it.
- ↳ Can be fabricated in a dental laboratory.

Porcelain Veneers:->

- ↳ Esthetic stability
- ↳ Stain resistant
- ↳ Stronger & durable
- ↳ Gum tissues tolerates porcelain well.
- ↳ The color of a porcelain veneer can be selected such that it makes dark teeth appear whiter.
- ↳ Veneers offers a conservative approach to changing a tooth's color & shape.
- ↳ Cannot be built in mouth
- ↳ Hence fabricated outside & fitted later.

Indications:->

- ↳ Esthetically compromised anterior teeth
- ↳ Poorly shaped, or crooked teeth.
- ↳ Stained teeth.
- ↳ Closure of diastemas
- ↳ Enamel hypoplasia.
- ↳ Fractured teeth.
- ↳ Tooth wear.
- ↳ Improve extreme discoloration such as
 - Tetracycline staining
 - Fluorosis
 - Devitalized teeth.
- ↳ Ability to lengthen anterior teeth.

Contraindications:->

- ↳ No enamel is present, full crown should be considered.
- ↳ Certain tooth-to-tooth habits bruxing or other para functional habits such as pencil chewing.
- ↳ Certain types of occlusal problem such as class III