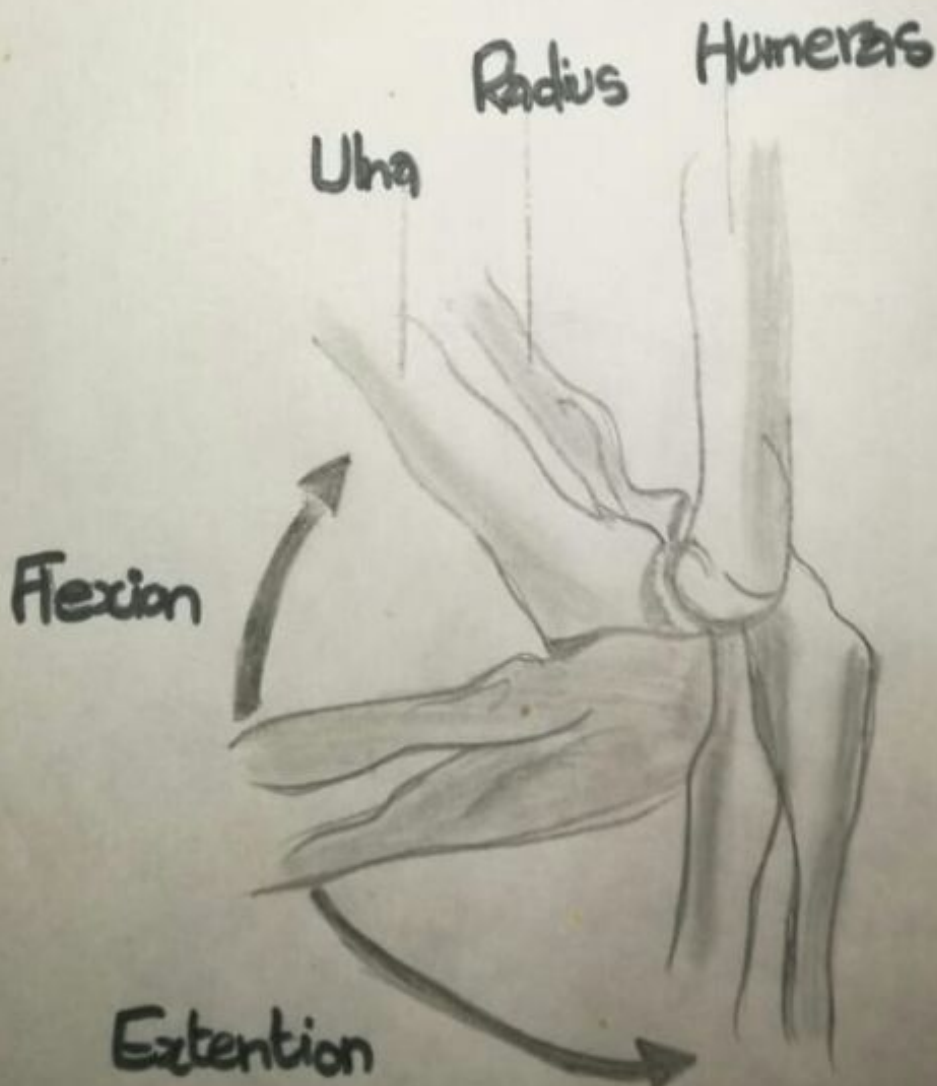
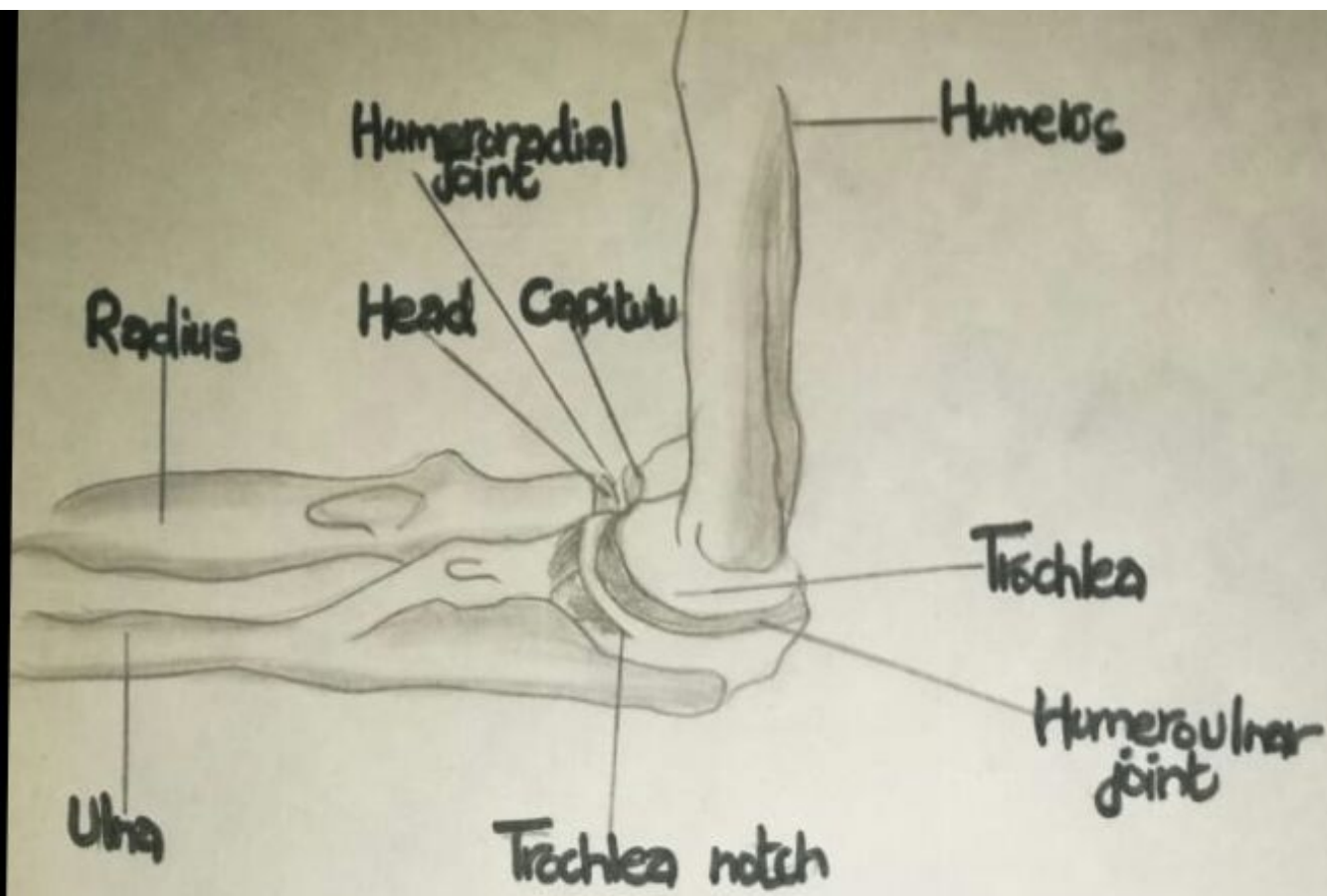
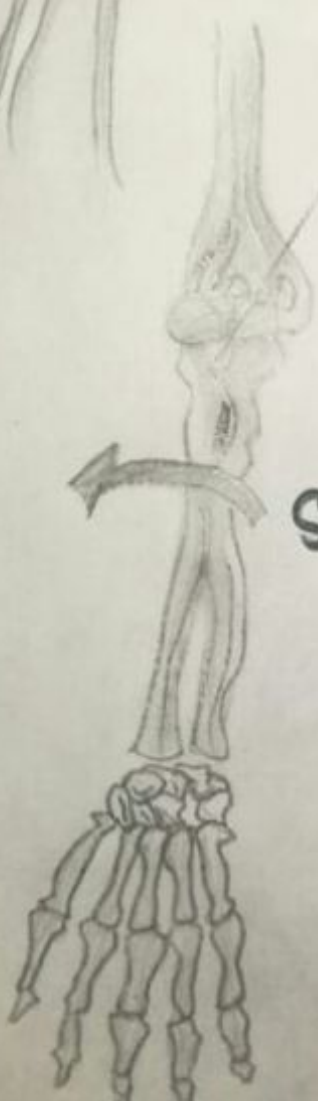
Supination

Pronation

Fovea of the head of the radius

Olecranon Process of Ulna

Proximal radioulnar joint



Supination



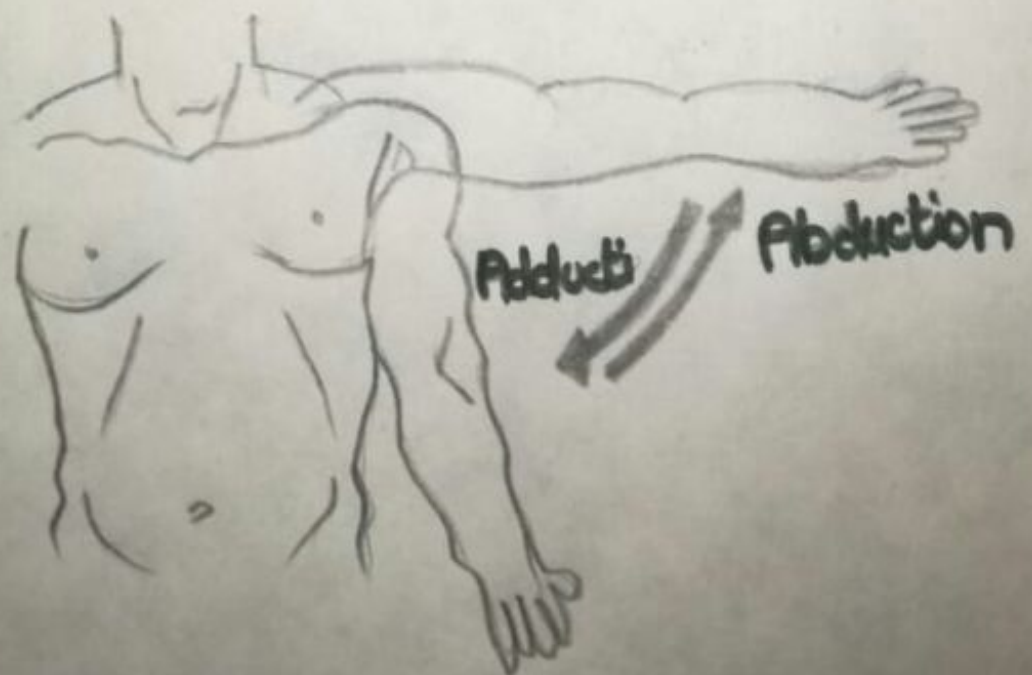
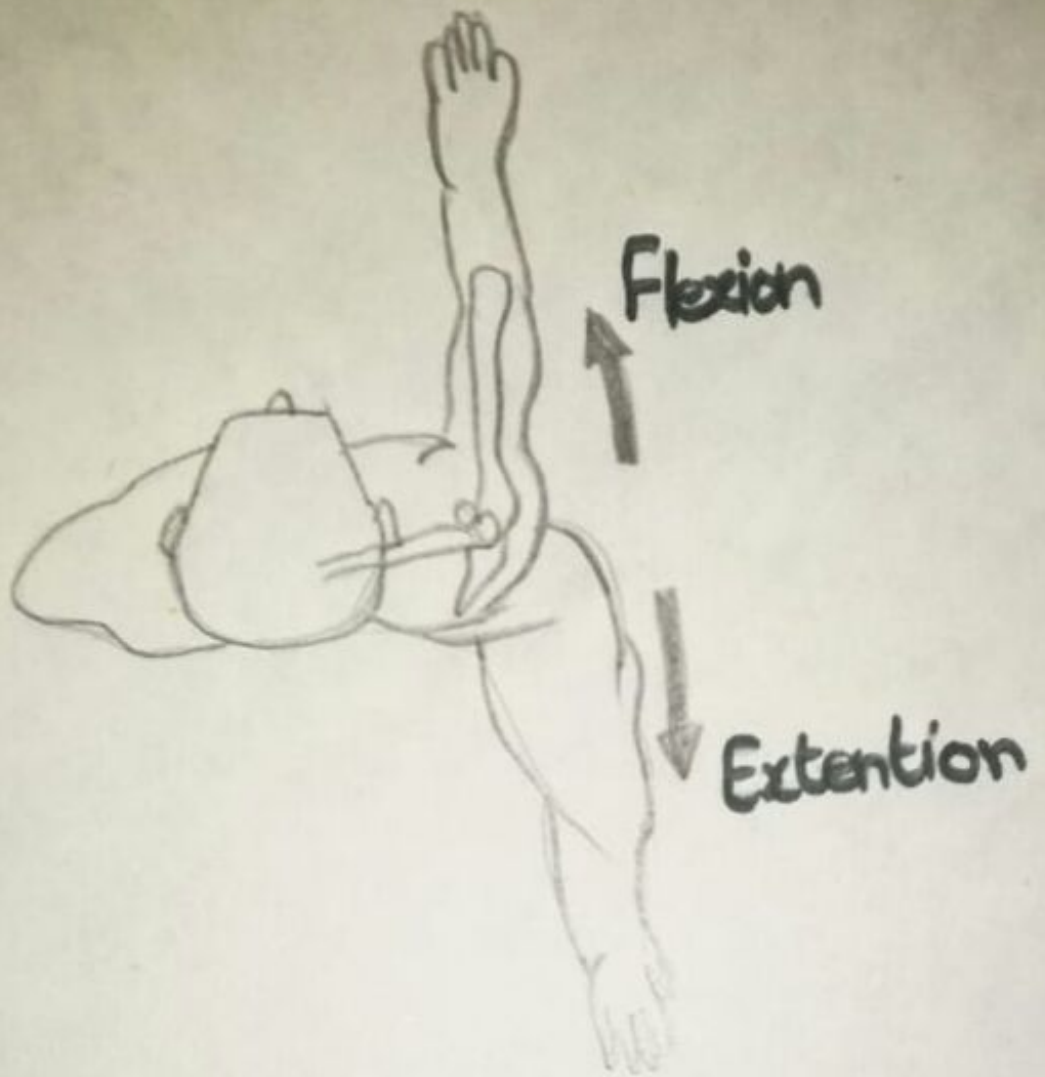
Pronation

A

Supinated Position

B

Pronated Position

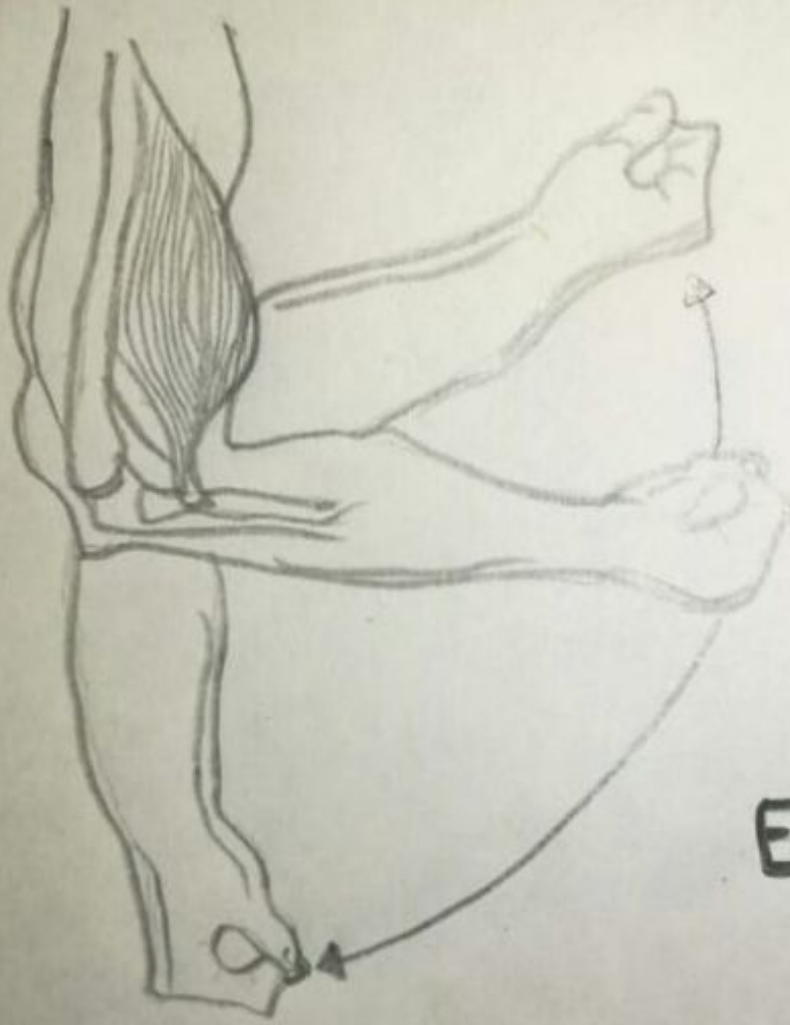




Internal rotation



External rotation



Flexion (concentric)

Extension (eccentric)

Radial deviation

Ulnar deviation

Roll

Roll

Glide

Glide

A

B

