

# **Human anatomy lab**

**Name Adil khan**

**ID 16876**

**Bs radiology**

Clavicule

SA  
acromiale

SA sternale




sillon du muscle  
subclavier

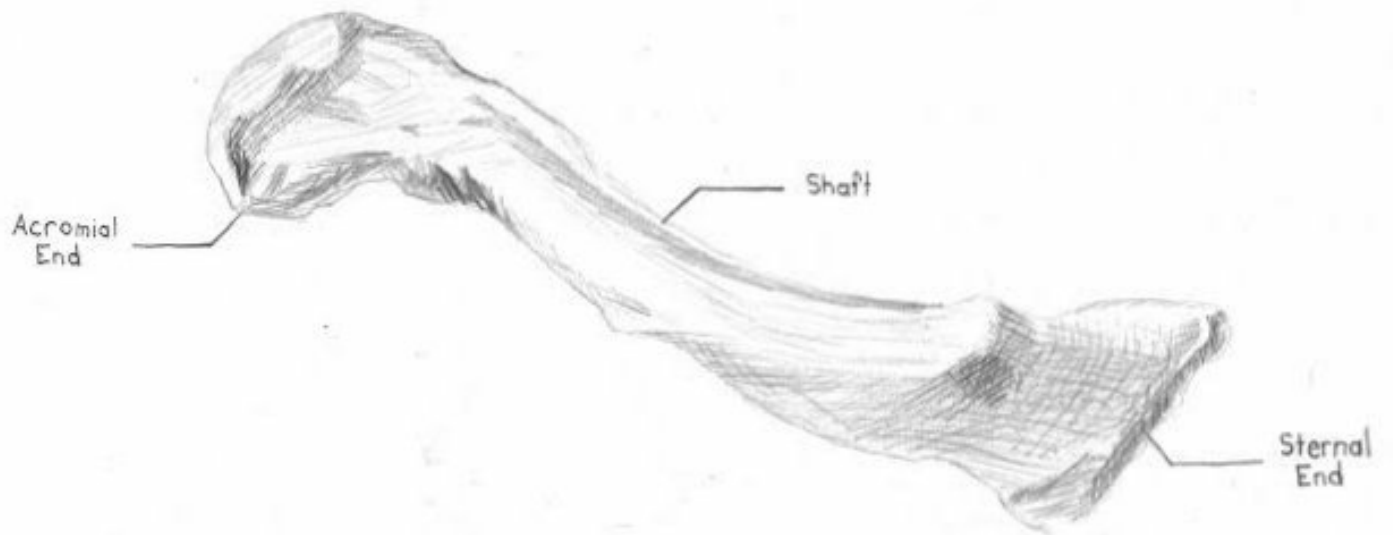
ligne  
trapézoïde

tubercule conoïde

Empreinte du  
ligament costo-claviculaire



# Clavicle



# Scapula

FRONT

Coracoid process

Costal surface

BACK

Acromion process

Spine

Dorsal surface

