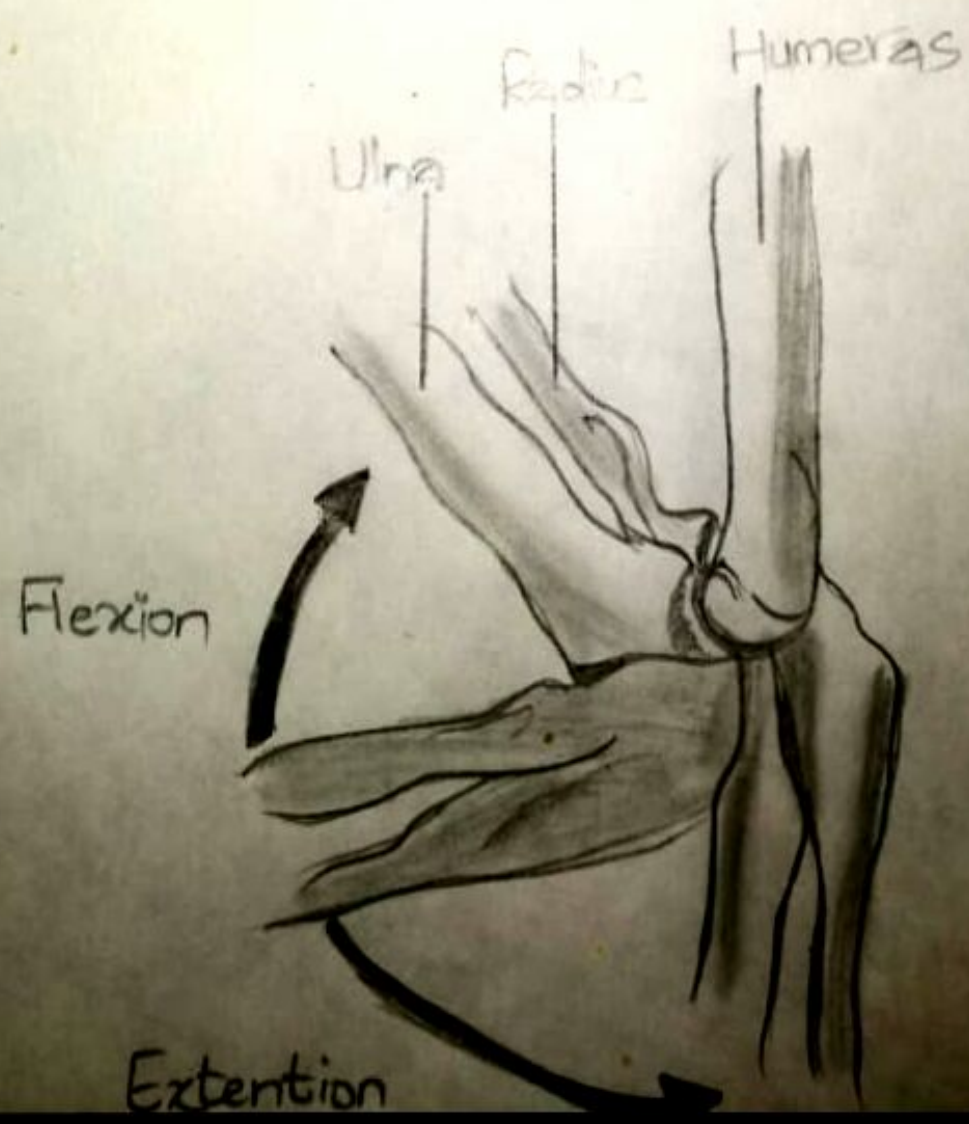
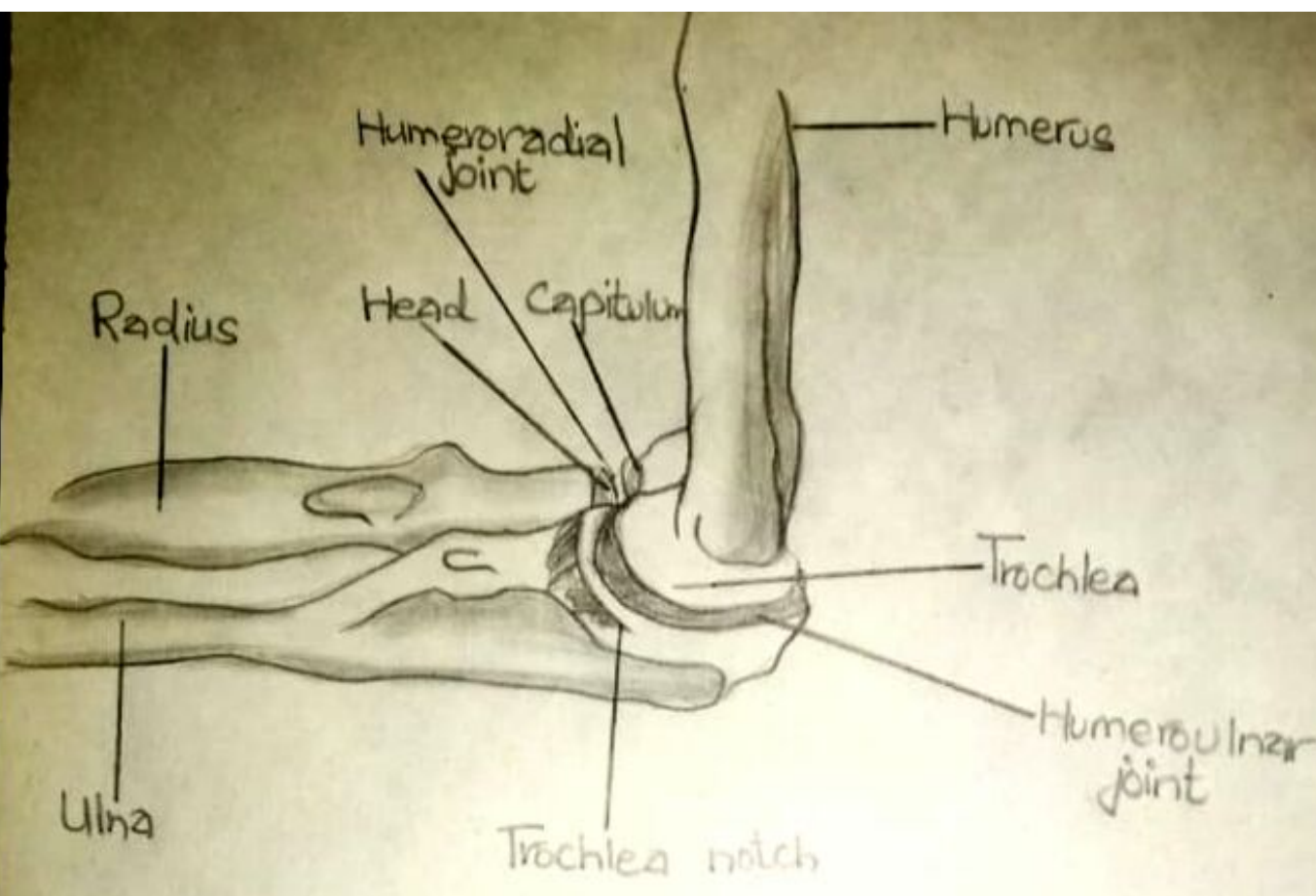
Supination

Fovea of the head of the radius

Olecranon Process of Ulna

Pronation

Proximal radioulnar joint

Supination

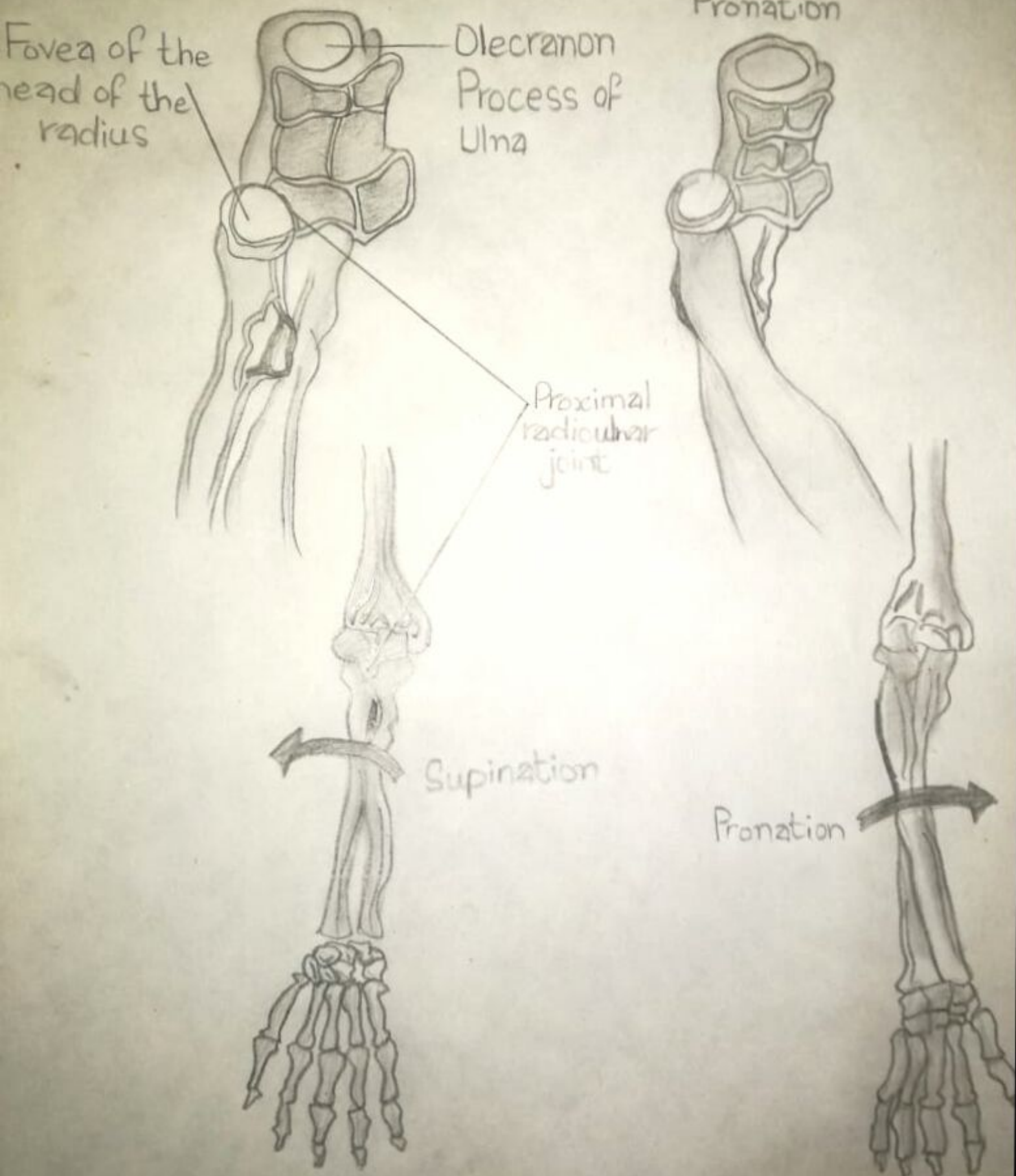
Pronation

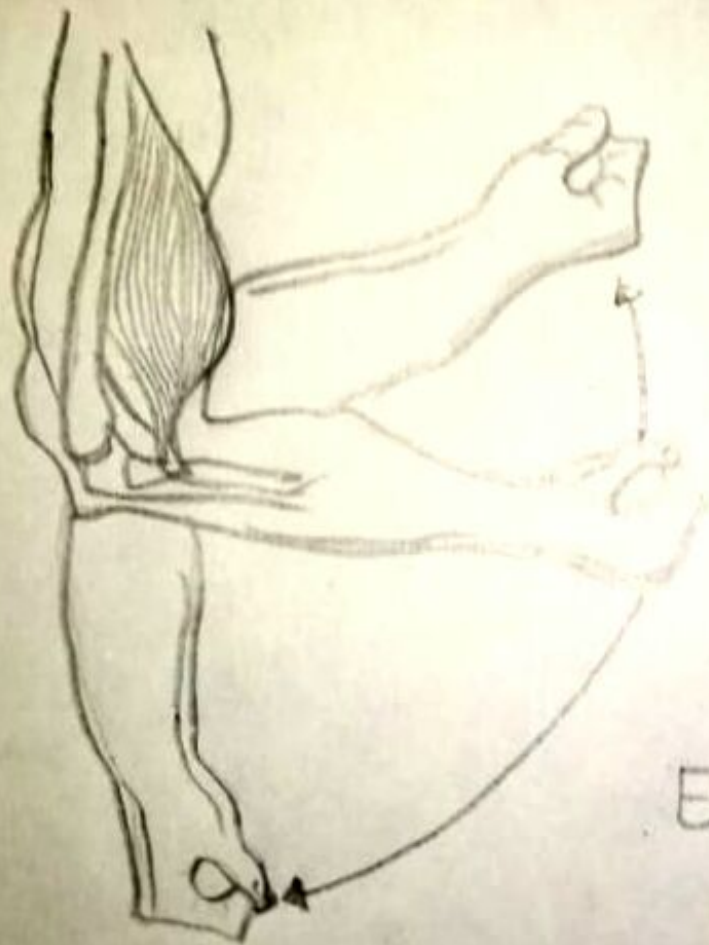
A

Supinated Position

B

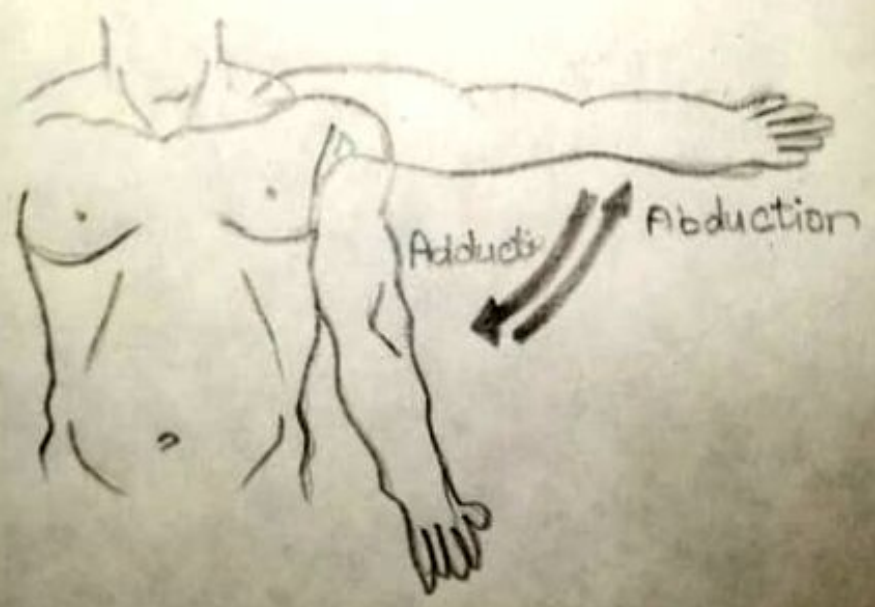
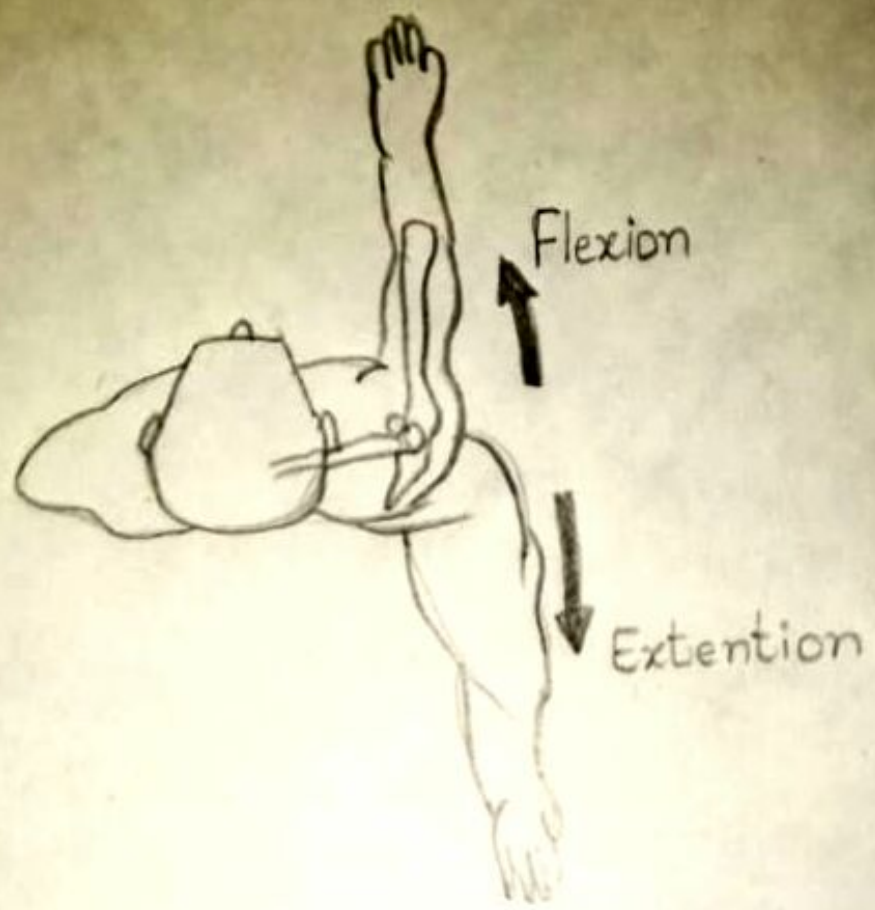
Pronated Position





Flexion (concentric)

Extension (eccentric)



Radial deviation

Ulnar deviation

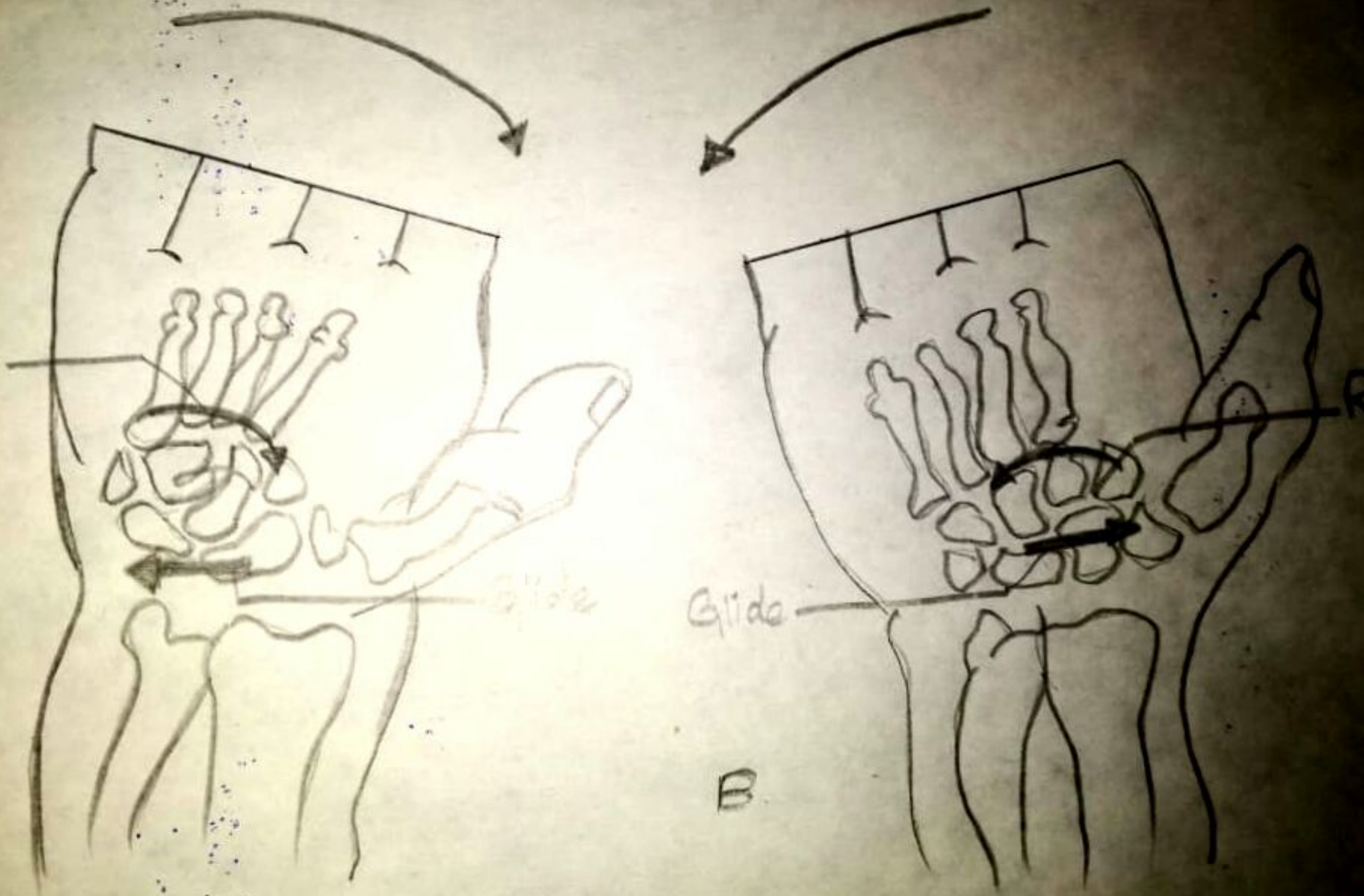
Roll

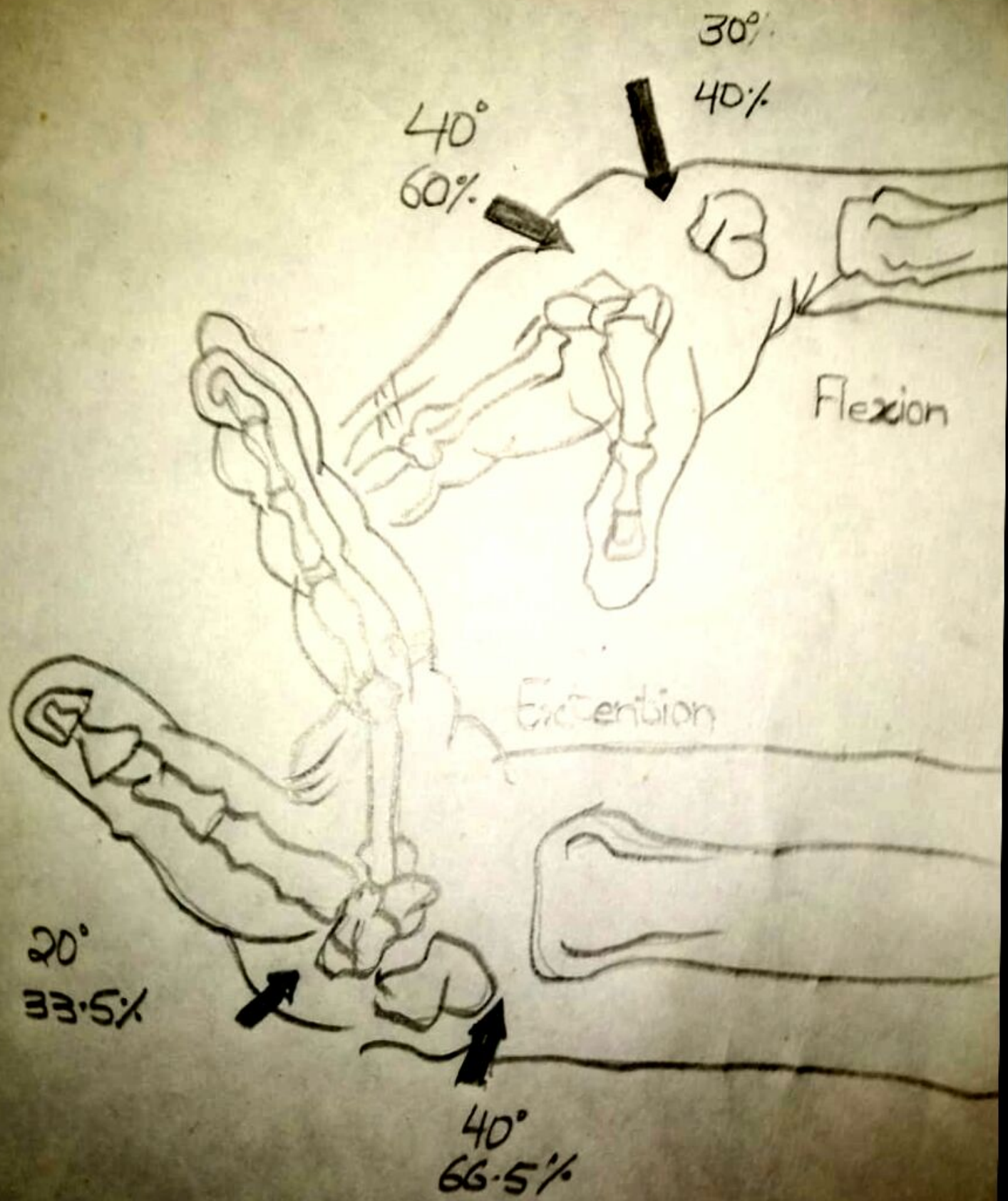
Glide

Glide

A

B







Internal rotation



External rotation