

DENTAL SEC A ANATMOY, 2ND SEMESTER, FINAL TERM

MAM KOUSAR SHAH JEHAN

STUDENT NAME __ibrar waheed_____, ID _____16485_____

Attempt all questions. Every question carry 10 marks.

Q1. Write a note on pituitary gland, its hormones and abnormalities

Ans:-**pituitary gland**:-It is a small structure in the head. It is called the master **gland** because it produces hormones that control other **glands** and many body functions including growth. ... These influences are exerted through the effects of **pituitary** hormones on other endocrine **glands** except for growth hormone which acts directly on cell.

Hormones secreted by pituitary gland

1. Anterior pituitary:

1. Growth hormone
- ii. Prolactin
- iii. Adrenocorticotropin hormone
- iv. Thyrotropin hormone
- v. Luteinizing hormone
- vi. Follicle stimulating hormone

2. Posterior pituitary:

- i. Oxytocin
- ii. Antidiuretic hormone

1. Growth hormone

- Somatotrin
 - Increases secretions at low glucose level.
 - Growth hormone promotes growth of almost all the body tissues
 - It promotes increase in size of cells, increased mitosis and differentiation of certain type of cells such as bone growth cells, muscle cells
- Abnormalities of growth hormone

2. Prolactin :-

- Milk production

3. Adrenocorticotropin hormone:-

- Acts on adrenal glands and secretes adrenocortical hormones
- Mainly cortisol..helps in stress condition

4. Thyroid stimulating hormone:-

- Act on thyroid gland release thyroxin
- Thyroid function... The **thyroid hormones** act on nearly every cell in the body. They act to increase the basal metabolic rate, affect protein synthesis, help regulate long bone growth

5. Luteinizing hormone follicle stimulating hormone:-

- These **hormones** are considered a gonadotrophic **hormone** because of its **role** in controlling the **function** of ovaries in females and testes in males, which are known as the gonads.

Posterior pituitary

- Oxiotxin. uterine contraction and milk production

- Antidiuretic hormone(ADH). water reabsorption from kidney tubules •When bp increase more water reabsorption occurs.

- Diabetes insipidus** (DI) is a condition characterized by large amounts of dilute urine and increased thirst.

Q2. write a note on shoulder joint and wrist joint*

Ans:-shoulder joint:-

The **shoulder joint** is formed by the articulation of the head of the humerus with the glenoid cavity (or fossa) of the scapula. This gives rise to the alternate name for the **shoulder joint** - the **glenohumeral joint**. Like most synovial **joints**, the articulating surfaces are covered with hyaline cartilage.

Type:-

☞ Synovial ball and socket joint

ARTICULATION

- This occurs between the rounded head of the humerus and the shallow, pearshaped glenoid cavity of the scapula.

- The articular surfaces are covered by hyaline articular cartilage

- The capsule is thin and lax, allowing a wide range of movement.

LIGAMENTS:

The glenohumeral ligaments are three weak bands of fibrous tissue that strengthen the front of the capsule.

The transverse humeral ligament strengthens the capsule and bridges the gap between the two tuberosities.

The coracohumeral ligament strengthens the capsule above and stretches from the root of the coracoid process to the greater tuberosity of the humerus.

ACCESSORY LIGAMENTS:

- The coracoacromial ligament extends between the coracoid process and the acromion.

- Its function is to protect the superior aspect of the joint.

SYNOVIAL MEMBRANE:

- This lines the capsule and is attached to the margins of the cartilage covering the articular surfaces.

Nerve supply:

- The axillary and suprascapular nerves

Movements:-

The following movements are possible

 Flexion

 Extension

! Abduction

! Adduction

! Lateral rotation

 Medial rotation

! Circumduction

DISLOCATIONS OF THE SHOULDER JOINT

The shoulder joint is the most commonly dislocated large joint.

Anterior Inferior Dislocation: Sudden violence applied to the humerus with the joint fully abducted tilts the humeral head downward onto the inferior weak part of the capsule, which tears, and the humeral head comes to lie inferior to the glenoid fossa.

POSTERIOR DISLOCATIONS

- Posterior dislocations are rare and are usually caused by direct violence to the front of the joint.

•A subglenoid displacement of the head can cause damage to the axillary nerve, as indicated by paralysis of the deltoid muscle and loss of skin sensation over the lower half of the deltoid. •Downward displacement of the humerus can also stretch and damage the radial nerve.

Wrist joint:-

The wrist is an ellipsoidal (condyloid) type synovial joint, allowing for movement along two axes. This means that flexion, extension, adduction and abduction can all occur at the wrist joint. All the movements of the wrist are performed by the muscles of the forearm.

Type:-synovial ellipsoid joint

Articulation

Above: The distal end of the radius.

Below: The scaphoid, lunate, and triquetral bones.

Capsule: The capsule encloses the joint and is attached:

Ligaments

- The medial ligament:
- The lateral ligament:

Anterior/palmar ligaments :

Posterior/dorsal ligament :

Synovial membrane:

•Nerve supply:

- Anterior interosseous nerve
- Deep branch of the radial nerve

Movements

The following movements are possible:

- Flexion
- Extension
- Abduction
- Adduction
- Circumduction

Q3.what is axilla and cubital fossa and its important contents?

Ans:- Axilla:-

The axilla or armpit is 4 sided pyramid-shaped space between upper part of arm and side of chest.

•It forms an important passage for nerves, blood, and lymph vessels as they travel from the root of the neck to the upper limb.

Boundaries:-

- Apex
- Base
- Anterior wall
- Posterior wall
- Medial wall •Lateral wall

Contents of axilla:-

- Axillary artery and its branches
- Axillary vein and its branches
- Brachial plexus
- Axillary lymph nodes

Cubital fossa:-

Cubital fossa is triangular depression situated on the front of the elbow .

Boundaries:

! Lateral

! Medial

! Superior

Contents of cubital fossa:-

The fossa contains the following structures from medial to lateral side.

1+Median nerve

2. The bifurcation of brachial artery into ulnar and radial arteries

3+ The tendon of biceps muscle

4+ Radial nerve and its deep branch

Q4+write a note on lower limb and its main important structures briefly?

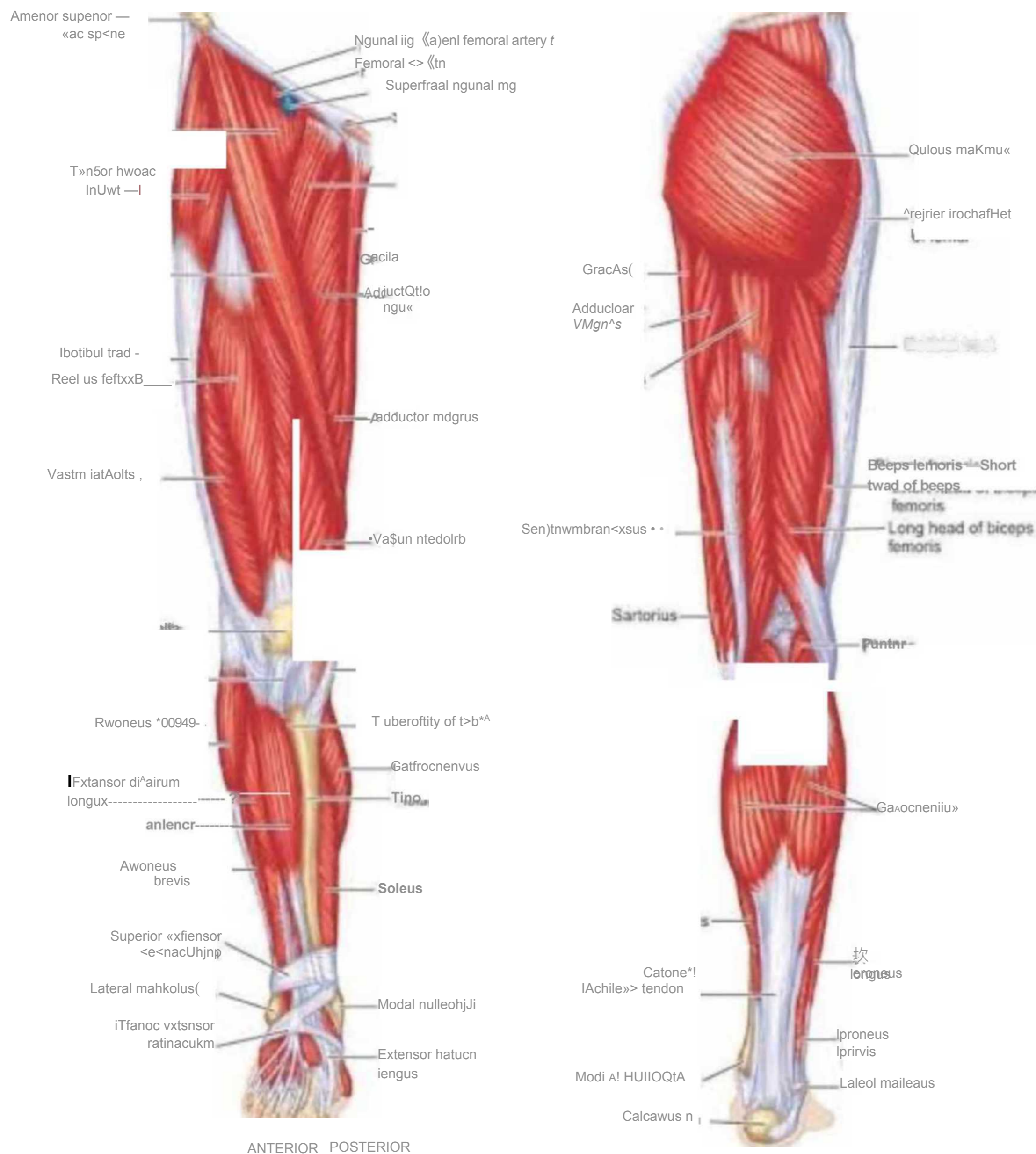
Ans:-Like the upper limb, the lower limb is divided into three regions. The thigh is that portion of the lower limb located between the hip joint and knee joint. The leg is specifically the region between the knee joint and the ankle joint. Distal to the ankle is the foot. The lower limb contains 30 bones. These are the femur, patella, tibia, fibula, tarsal bones, metatarsal bones, and phalanges. The femur is the single bone of the thigh. The patella is the kneecap and articulates with the distal femur. The tibia is the larger, weight-bearing bone located on the medial side of the leg, and the fibula is the thin bone of the lateral leg. The bones of the foot are divided into three groups. The posterior portion of the foot is formed by a group of seven bones, each of which is known as a tarsal bone, whereas the mid-foot contains five elongated bones, each of which is a metatarsal bone. The toes contain 14 small bones, each of which is a phalanx bone of the foot.

Importance of lower limb:-

The lower limb is designed for weight-bearing, balance, and mobility.

The bones and muscles of the lower limb are larger and stronger than those of the upper limb, which is necessary for the functions of weight-bearing and balance. Our lower limbs carry us, allow us to push forward, and also keep us standing still. Our sense of steadiness and strength often comes from our lower limbs.

The muscles of the thigh are thick and strong and can tolerate greater pressure during massage than the smaller muscles of the arm. Petrissage is generally welcome and easy to perform in the thigh. The muscles of the posterior leg are also thick and strong,



Q5.(i) A person fell down from a tree and become unconscious, with bleeding from head, what will you do as a first aid?

Ans:-If severe head trauma occurs

1 Keep the person still. Until medical help arrives, keep the injured person lying down and quiet, with the head and shoulders slightly elevated....

2 Stop any bleeding. Apply firm pressure to the wound with sterile gauze or a clean cloth....

Watch for changes in breathing and alertness

4 if they are breathing - roll them into the recovery position (on their side so that their tongue falls forward in their mouth and any vomit can drain away), trying not to twist their neck or spine at all.

5 Any head injury could have caused spinal damage as the head recoils from the blow.

6 If they are not breathing start CPR.

7 Call for an ambulance.

(ii) you have to meet with your friend and you came to know he is covid positive, what precautionary measures will you take?

Ans:-1Wash your hands often with soap and water for at least 20 seconds especially after you have been in a public place, or after blowing your nose, coughing, or sneezing.

2

Avoid close contact with people who are sick, even inside your home. If possible, maintain 6 feet between the person who is sick and other household members

.Stay at least 6 feet (about 2 arms' length) from other people.

3

Cover your mouth and nose with a cloth face cover when around others

4

Cover coughs and sneezes

If you are around others and do not have on your cloth face covering, remember to always cover your mouth and nose with a tissue when you cough or sneeze or use the inside of your elbow and do not spit.

6

Clean AND disinfect frequently touched surfaces daily. This includes tables, doorknobs, light switches, countertops, handles, desks, phones, keyboards, toilets, faucets, and sinks.