

Name : Aqsa shoaib  
ID : 14967

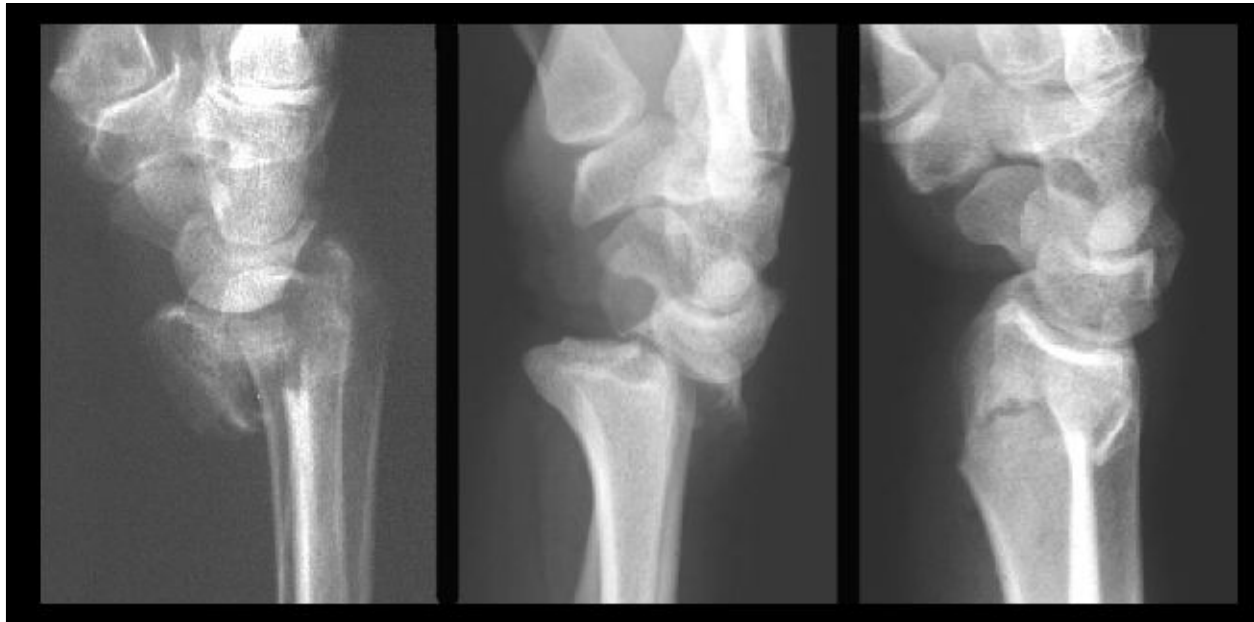
Viva: Positioning

Submitted to : Mam Atoofah azmat

Identify the radiological findings and pathologies in the following case studies.

CASE

11



ANSWER:

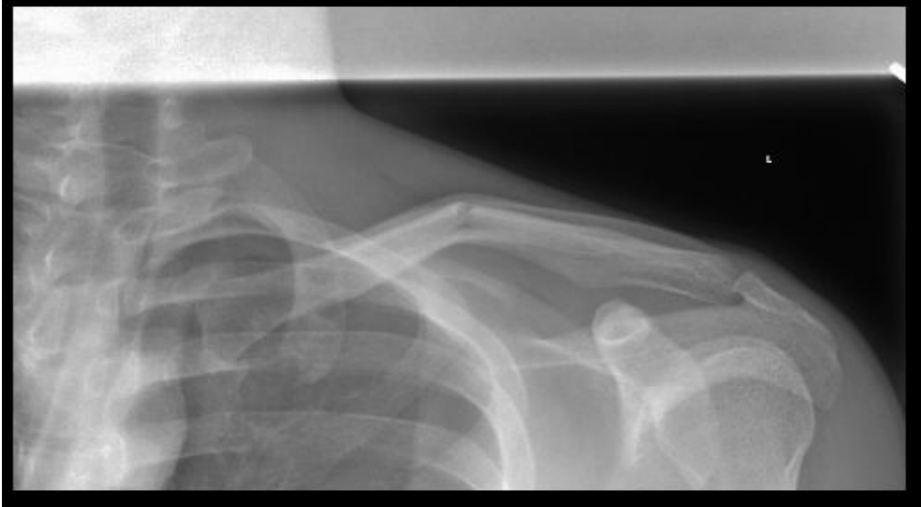PATHOLOGIES:

- 1:Giant cell tumor of the lower end of the radius.
- 2:Wrist joint dislocation.
- 3:(Colle's fracture) Fracture of lower end of radius.

RADIOLOGICAL FINDINGS:

- Giant cell tumor can be seen on the distal head of radius in the wrist joint.
- The distal head of the radius can be seen dislocated from it's normal position i.e the Anatomy of the wrist joint is distributed as the radius has moved away from it's anatomical position.

CASE-2



ANSWER:

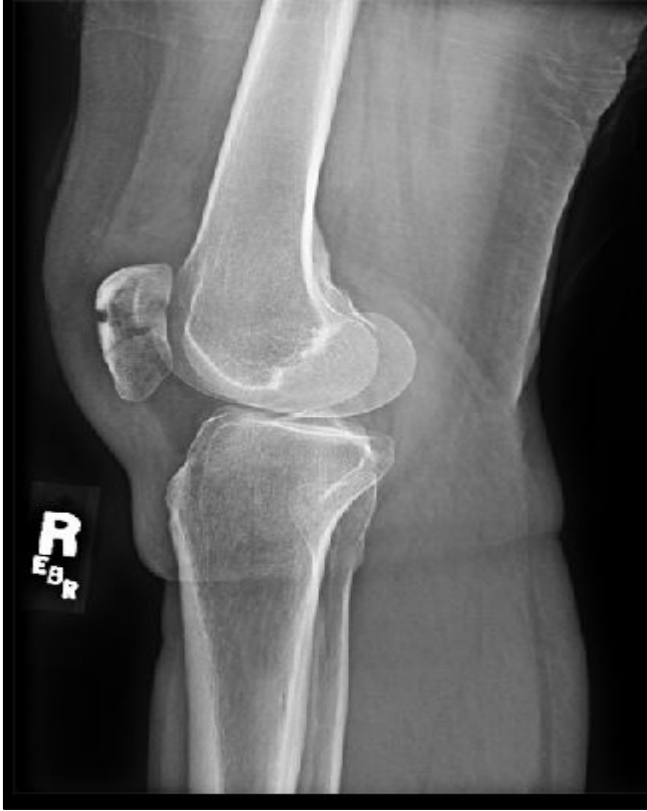PATHOLOGIES :

1: Left clavicular fracture

RADIOLOGICAL FINDINGS:

- The clavicle can be seen as elevated upward in the middle of the shaft.

CASE 3



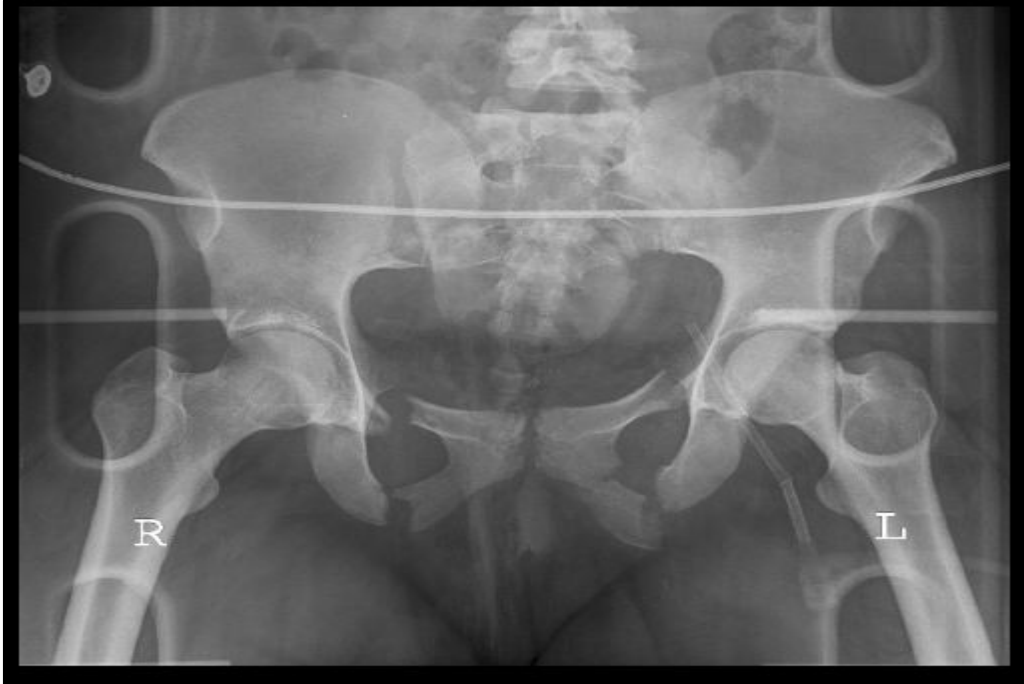ANSWER:PATHOLOGIES:

1:Patellar fracture.

RADIOLOGICAL FINDINGS:

- The patella i.e sesamoid bone present just anterior to the knee joint in the tendon of the quadratus femoris muscle,can be seen clearly fractured.

CASE 4



ANSWER:

PATHOLOGIES:

1: Unstable pubic rami fracture

RADIOLOGICAL FINDINGS:

- The pubic Bone of the pelvis has two rami on each side i.e on the left and right.
- It can be seen clearly that the rami on each side has been broken.
- The pubic bone has two rami on each side i.e superior and inferior on left and the same superior and inferior on right.
- We can see that both the superior and inferior rami of left and right sides has broken resulting into an Unstable Pubic Rami Fracture.

End of viva..!!!